Journal of Gastrointestinal Surgery (2023) 27:1510–1529
https://doi.org/10.1007/s11605-023-05634-8

Biliary Anatomy 2.0 Quiz: Test Your Knowledge

Mateo Lendoire[1] · Harufumi Maki[1] · Antony Haddad[1] · Anish J. Jain[1] · Jean-Nicolas Vauthey[1]

Received: 23 January 2023 / Accepted: 11 February 2023 / Published online: 20 April 2023
© The Society for Surgery of the Alimentary Tract 2023

Abstract
Anatomy has remained an interest of physicians throughout the ages. The biliary tract spans from the liver to the hepatoduodenal mesentery, pancreas, and into the duodenum. Therefore, it is important for not only hepatobiliary surgeons but also general gastrointestinal surgeons, gastroenterologists, radiologists, and pathologists to be familiar with biliary anatomy and its variants. While surgery for hilar cholangiocarcinoma is one of the most challenging procedures, cholecystectomy is one of the most common procedures done from the beginning of surgical training. We hope that by answering the following questions, you will gain a comprehensive understanding of biliary anatomy and a greater appreciation for it.

Keywords Biliary anatomy · Biliary tree · Gallbladder · Bile ducts · Anatomy · Quiz · Questionnaire · Test

Biliary Anatomy Exam: 79 Questions, Multiple Choice/Matching

This quiz is intended for general and hepatopancreatobiliary (HPB) surgeons. Select the best answer (only one correct answer per question) to the following multiple-choice questions about biliary tract anatomy and related topics.

This is a challenging quiz. Therefore, a score of 50% means you have a *good* knowledge of hepatobiliary anatomy, and a score of 70% or more means your knowledge about biliary anatomy is *excellent*.

1. What are the most common locations of the common bile duct arteries?

   a. Anterior and posterior (12 and 6 o'clock)
   b. Left and right (3 and 9 o'clock)
   c. Just anterior (12 o'clock)
   d. Just right (9 o'clock)

Choose the anatomic structure that matches what is shown in the illustration:

2. Common bile duct: ___
3. Common hepatic duct: ___
4. Cystic duct: ___
5. Gallbladder: ___
6. Right hepatic duct: ___
7. Left hepatic duct: ___

✉ Jean-Nicolas Vauthey
jvauthey@mdanderson.org

[1] Department of Surgical Oncology, The University of Texas MD Anderson Cancer Center, 1515 Holcombe Boulevard, Unit 1484, Houston, TX 77030, USA

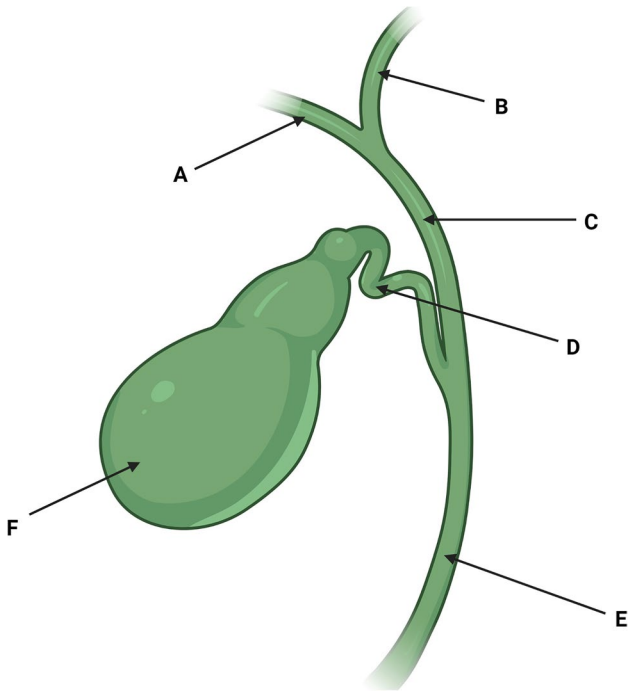

From the illustration below, please identify which bile duct each alphabetical label corresponds to:

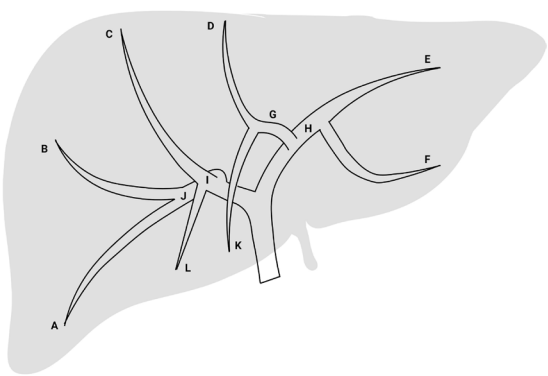

8. Left lateral sectoral: ___
9. Left medial sectoral: ___
10. Segment V: ___
11. Segment VI: ___
12. Segment VII: ___
13. Segment IVa: ___
14. Segment II: ___
15. Right posterior sectoral: ___
16. Segment VIII: ___
17. Segment IVb: ___
18. Right anterior sectoral: ___
19. Segment III: ___

20. Which of the following structures is NOT part of the extrahepatic biliary tree?

    a. Left hepatic duct
    b. Anterior sectoral right hepatic duct
    c. Gallbladder
    d. Common hepatic duct

21. How much bile is produced in one day?

    a. 650 ml per day
    b. 850 ml per day
    c. 1250 ml per day
    d. 1550 ml per day

22. What is the arterial blood supply to the retropancreatic bile duct?

    a. Dorsal pancreatic artery
    b. Right gastric artery
    c. Gastroduodenal artery
    d. Retroduodenal artery

23. The left hepatic duct is consistently present in most patients. However, in what proportion is the left hepatic duct completely absent?

    a. 0.05%
    b. 3%
    c. 15%
    d. 41%

24. Which segments does the anterior sectoral right hepatic duct drain?

    a. V and VI
    b. V and VIII
    c. VI and VII
    d. VII and VIII

25. Which hepatic duct is more frequently associated with anatomic variations?

    a. Right
    b. Left
    c. Both have a similar incidence of anatomic variations

26. What is the embryologic origin of the extrahepatic bile duct?

    a. Mesoderm
    b. Ectoderm
    c. Endoderm

d. Hindgut

27. How frequently does the cystic duct drain to the right hepatic duct?

a. Less than 1%
b. 14%
c. 27%
d. 48%

28. Which lymph node station is located along the common hepatic artery?

a. 12
b. 11
c. 9
d. 8

29. Choose the artery that does NOT provide blood supply to the extrahepatic bile duct.

a. Right hepatic
b. Posterior superior pancreaticoduodenal
c. Retroportal
d. Left gastric

30. How many tributaries of the biliary tree drain segment I?

a. 1 or 2
b. 3 or 4
c. 7 or 8
d. 9 or 10

31. Choose the correct statement about the retroportal artery.

a. It originates from the proper hepatic artery
b. It does not provide blood supply to the extrahepatic bile duct
c. It can originate from either the coeliac axis or the superior mesenteric artery
d. It is a fickle artery

32. Which hepatic segments does the left hepatic duct typically drain?

a. I, II, III, and IV
b. II, III, IV, and V
c. V, VI, VII, and VIII
d. II and III

33. Which of the following corresponds to a normal biliary anatomy?

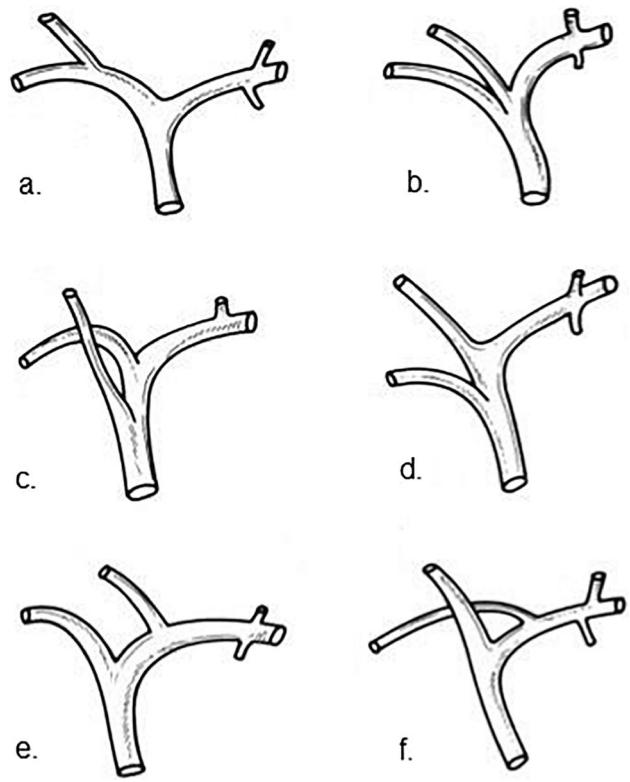

Answer: ___

34. In the previously shown figure, which is the most frequent anatomical variation?

Answer: ___

35. Following a Whipple procedure, there is bile in the drain. Which of the following is a possible source of this leak?

a. Liver injury
b. Hepaticojejunostomy
c. Posterior sectoral right hepatic duct
d. All of the above

36. Select the most common confluence pattern of the right intrahepatic bile ducts described by Ohkubo et al.:

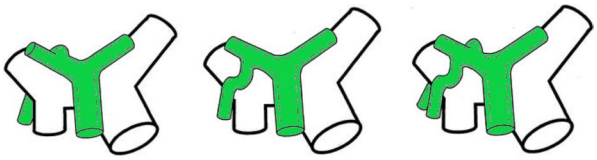

a b c

Answer: ___

37. A 54-year-old patient presents with history of jaundice. Magnetic resonance cholangiopancreatography shows an obstruction of the biliary tree. Please choose the correct location of the obstruction.

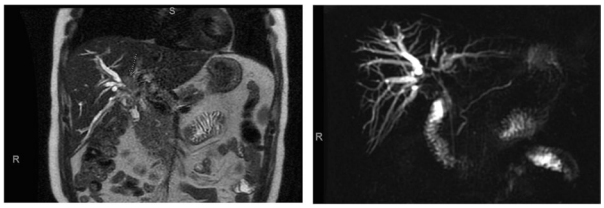

a. Left hepatic duct
b. Right posterior duct
c. Right hepatic duct
d. Common hepatic duct

38. A 64-year-old male presents a liver mass on CT (computed tomography) scan. It reveals occlusion of the right portal vein and right-sided bile duct dilation. What most accurately describes the following two images?

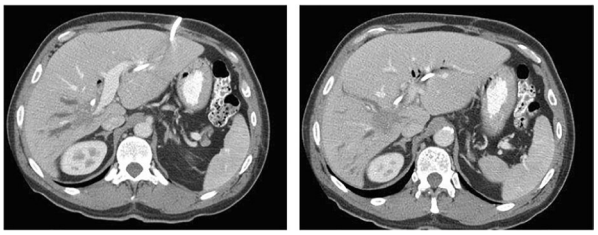

a. Cholestasis
b. Congestive right liver
c. Ischemia–reperfusion injury
d. Atrophy-hypertrophy complex

With the image presented in the previous question, underwent an extended right hepatectomy with hilar lymphadenectomy and portal vein reconstruction. Match the anatomic structures with the alphabetical labels shown in the figure:

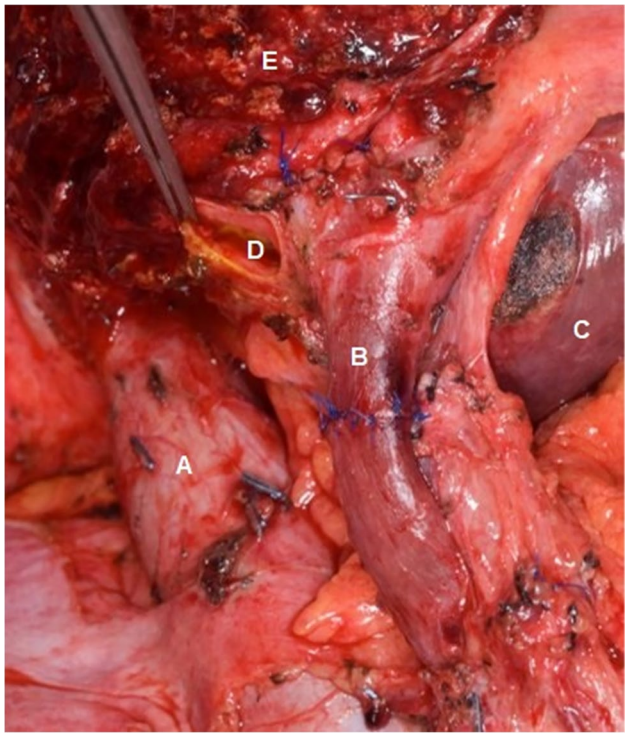

39. Liver capsule: ___
40. Left hepatic duct: ___
41. Inferior vena cava: ___
42. Liver transection plane: ___
43. Portal vein: ___

44. In the following images, which segments do NOT show bile duct dilation?

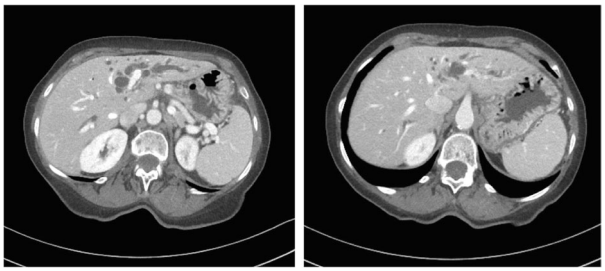

a. II, III
b. VI, VII
c. V, VIII
d. IV, V

45. Who was the first to introduce intraoperative cholangiography in surgical practice?

    a. Claude Couinaud
    b. Carl Hjortsjo
    c. Erich Mühe
    d. Pablo Mirizzi

46. What is Mirizzi's syndrome?

    a. It is a malignant obstruction of the common hepatic duct obstruction due to gallbladder cancer
    b. It is a benign obstruction of the common hepatic duct due to gallstone impaction in the gallbladder neck
    c. It is a malignant obstruction of the common hepatic duct due to hilar cholangiocarcinoma
    d. It is a benign obstruction of the common hepatic duct due to stones in the biliary tract

47. Which of the following is NOT a predisposing factor for the development of Mirizzi's syndrome?

    a. Long cystic duct
    b. Cystic duct with a parallel course to the common bile duct
    c. Low insertion of the cystic duct
    d. Gallstone > 1 cm

48. Select the correct statement:

    a. Bile from the caudate lobe drains into both the right and left hepatic ducts near the confluence
    b. Hilar cholangiocarcinoma rarely invades segment I
    c. The caudate lobe forms part of the anterior limit of the hilar plate
    d. The caudate process is the most readily identified portion of segment I

49. What common bile duct width is highly indicative of biliary obstruction?

    a. > 8 mm
    b. > 10 mm
    c. > 12 mm
    d. > 14 mm

50. Which factor is associated with an increase in the common bile duct diameter without obstruction?

    a. > 70 years old
    b. Previous cholecystectomy
    c. Opiate users
    d. All of the above

51. What is the most frequent bacterial colonizer of the bile duct?

    a. *Escherichia coli*
    b. *Staphylococcus aureus*
    c. *Klebsiella pneumoniae*
    d. None, bile is sterile in normal conditions

52. Intraoperatively, which is an essential study to assess biliary anatomy?

    a. Magnetic resonance cholangiopancreatography (MRCP)
    b. Cholangiography
    c. Endoscopic retrograde cholangiopancreatography (ERCP)
    d. Ultrasound

53. Who was the first to describe the sheaths surrounding the portal pedicles?

    a. Francis Glisson
    b. Johannes Walaeus
    c. J. E. Healey Jr
    d. Hugo Rex

54. What is the structure depicted by the yellow arrow?

a. Right hepatic duct
b. Segment VII bile duct
c. Segment V bile duct
d. Right anterior sectoral duct

55. What is the double duct sign in radiographic imaging and what does it mean?

a. It shows simultaneous dilation of the common bile duct and the pancreatic duct. It is most commonly due to a mass in the pancreatic head
b. It shows both the common bile duct and cystic duct adjacent to each other. This signifies an anatomic variation of the cystic duct
c. It shows the dilation of both the main and accessory pancreatic duct, and signifies a mass in the pancreatic head
d. It shows and signifies dissected common bile duct wall

56. Which of the following statements about the structure indicated by the yellow arrow is true?

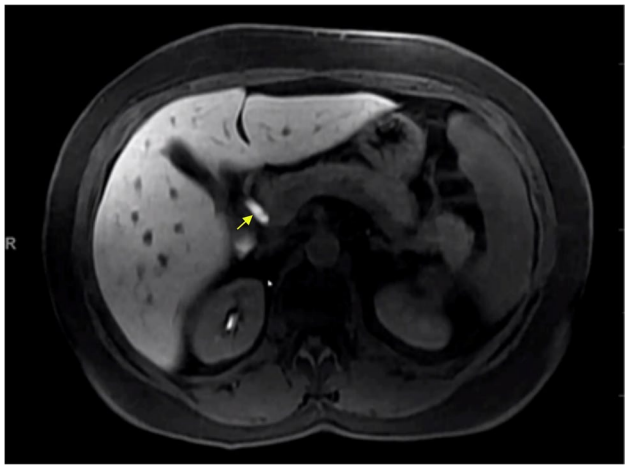

a. This is the common hepatic artery and is seen after 25 s of contrast infusion with gadolinium
b. This is the common bile duct and is seen after 20 min of contrast infusion on MR Eovist
c. This is the proper hepatic artery and is seen after 15 s of contrast infusion with gadolinium
d. None of the above

57. Which is the most frequently observed anatomical variation of the pancreaticobiliary junction?

a. Both ducts enter the duodenum separately, no ampulla is present (85%)
b. Both ducts enter together, but the common channel is short, and no true ampulla is present (85%)
c. There is a long common channel that may or may not be dilated to form an ampulla (85%)
d. Junction of the ducts take place at the third portion of the duodenum, and the common channel always presents an ampulla (85%)

58. Which of the following statements about choledochal cysts is true?

    a. Most of them are diagnosed within the first decade of life
    b. They are most common in females and Asian population
    c. Pancreaticobiliary maljunction is the most common etiology of this entity
    d. All of the above

59. Which type of choledochal cyst is depicted in the illustration? What is its relative frequency?



    a. Type II, it is the least common
    b. Type IVb, it is the least common
    c. Type I, it is the most common
    d. Type V, it is the most common

60. What should be the correct treatment strategy for this type of choledochal cyst?

    a. ERCP with stent placement
    b. Extrahepatic bile duct cyst excision, cholecystectomy, and bilioenteric reconstruction
    c. Cystenterostomy
    d. All of the above

61. Which of the following statements best describes Caroli's disease?

    a. It presents with multiple intrahepatic bile duct cysts
    b. It consists of rounded or oval intrahepatic bile duct dilatations separated by segments of normal caliber
    c. Treatment consists of biliary drainage, resection or liver transplant depending on its extension
    d. All of the above

62. The gallbladder is divided into:

    a. Fundus, infundibulum, neck
    b. Fundus, body, neck
    c. Fundus, body, infundibulum, Hartman's pouch, neck
    d. Fundus, body, infundibulum, neck, cystic duct

63. Which hepatic segments form the gallbladder bed?

    a. IVa and V
    b. IVb and VI
    c. IVb and V
    d. IVa and V

64. Choose the layer that is absent in the gallbladder wall:

    a. Mucosa
    b. Submucosa
    c. Muscular
    d. Serosa

65. What is the triangle of Calot?

    a. It is an anatomic space bordered by the cystic duct inferiorly, the common hepatic duct medially, and the inferior surface of the liver superiorly
    b. It is the liver surface that is in touch with the duodenum
    c. It is the deperitonized liver surface
    d. It is an anatomic space bordered by the right hepatic artery inferiorly, the common hepatic duct medially, and the inferior surface of the liver superiorly

66. The triangle of Calot contains which of the following structures:

    a. Cystic artery
    b. Cystic lymph node of Lund
    c. Right hepatic artery
    d. All of the above

67. Which is a requirement to achieve a critical view of safety during laparoscopic cholecystectomy?

    a. The triangle of Calot cleared of fat and tissue
    b. The lowest part of the gallbladder should be separated from the cystic plate
    c. Two structures, and only two, should be seen entering the gallbladder
    d. All of the above

68. A normal non-inflamed gallbladder has:

    a. A wall thickness of 8 mm or less
    b. Pericholecystic fluid
    c. Its anteroposterior diameter of less than 40 mm
    d. Sludge

69. Which of the following statements about the cystic duct is true?

    a. It most commonly inserts on the left lateral aspect of the common bile duct
    b. Low insertion is defined as its insertion at the lower third of the common hepatic duct
    c. A short cystic duct is defined as < 10 mm long
    d. None of the above

70. What is the definition of a left-sided gallbladder?

    a. The gallbladder located to the left of the ligamentum teres
    b. The gallbladder located to the left of the common bile duct
    c. The gallbladder located to the left of the portal vein
    d. The gallbladder located at the left upper quadrant

71. Who was the first to ever perform a laparoscopic cholecystectomy?

    a. Claude Couinaud
    b. Carl Hjortsjo
    c. Erich Mühe
    d. Pablo Mirizzi

72. What is a duct of Luschka?

    a. It is a segment I bile duct that drains directly in the common hepatic duct
    b. It is a segment V aberrant duct draining directly into the common hepatic duct
    c. It is a hepaticocholecystic bile duct that always runs into the gallbladder
    d. It is a subvesical bile duct that either runs superficially close to or inserts in the gallbladder

73. The gallbladder is in contact with which of the following organs?

    a. Liver
    b. Duodenum
    c. Transverse colon
    d. All of the above

74. Which of the following statements about the duplicated gallbladders is true?

    a. It occurs much more frequently in humans than in animals
    b. They always share a common cystic duct
    c. Differential diagnosis includes folded gallbladder, a gallbladder diverticulum, a choledochal cyst, pericholecystic fluid, and focal adenomyomatosis
    d. A and C are correct

75. Which of the following statements about gallbladder polyps is true?

    a. Transabdominal ultrasound is the first-line imaging study for diagnosis, but in certain cases cross-sectional imaging is necessary
    b. Factors that suggest malignancy are: > 50 years old, larger than 1.5 cm, growth, sessile, solitary, and heterogeneous enhance pattern
    c. Small (< 1 cm), asymptomatic polyps should be monitored for 12 months with control ultrasound scans
    d. All of the above

76. Which of the following about the cystic artery and its frequency of variants is true?

    a. 74.7% of the time the cystic artery arises from the right hepatic artery
    b. 2.5% of the time the cystic artery arises from the gastroduodenal artery
    c. 20.5% of the time the cystic artery arises from the left hepatic artery
    d. All of the above

77. What is a "Phrygian cap" deformity of the gallbladder?

    a. The presence of a small accessory gallbladder attached to the main one
    b. A partial folding of the fundus of the gallbladder
    c. An almost completely intrahepatic gallbladder with only the fundus exposed
    d. A benign circumferential tumor of the gallbladder

78. What is the diagnosis associated with the imaging presented below?

    a. This is a "beads on a string" appearance of the bile ducts. It signifies primary biliary cholangitis
    b. This is a "beads on a string" appearance of the bile ducts. It signifies primary sclerosing cholangitis.
    c. This is onion skinning appearance, and it signifies primary sclerosing cholangitis.
    d. This is onion skinning appearance, and it signifies primary biliary cholangitis

79. What are the possible causes of the sign depicted in the image?

    a. Air in the biliary tree caused by bile duct stenting
    b. Blood in the biliary tree caused by bile duct stenting
    c. Air in the biliary tree caused by a pancreatic head mass
    d. Blood in the biliary tree caused by tumoral invasion

Answers:

1. What are the most common locations of the common bile duct arteries?[1]

    a. Anterior and posterior (12 and 6 o'clock)
    b. **Left and right (3 and 9 o'clock)**
    c. Just anterior (12 o'clock)
    d. Just right (9 o'clock)

Explanation for question 1: Northover et al.[1] shed light on this arterial distribution surrounding the biliary tree. Actually, the 3 o'clock and 9 o'clock arteries are the main trunks of a vascular network.[2]

Choose the anatomic structure that matches what is shown in the illustration[3]:

2. Common bile duct: **E**
3. Common hepatic duct: **C**
4. Cystic duct: **D**
5. Gallbladder: **F**

6. Right hepatic duct: **A**
7. Left hepatic duct: **B**

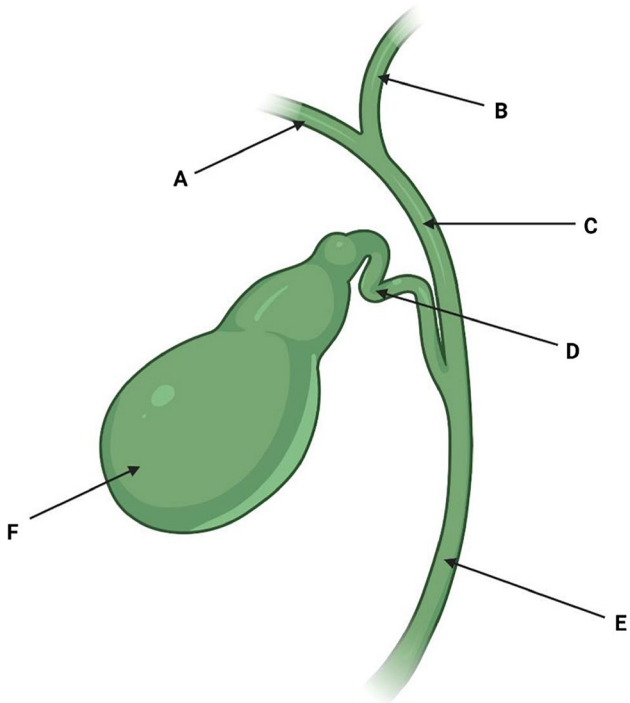

From the illustration below, please Identify which bile duct each alphabetical label corresponds to:

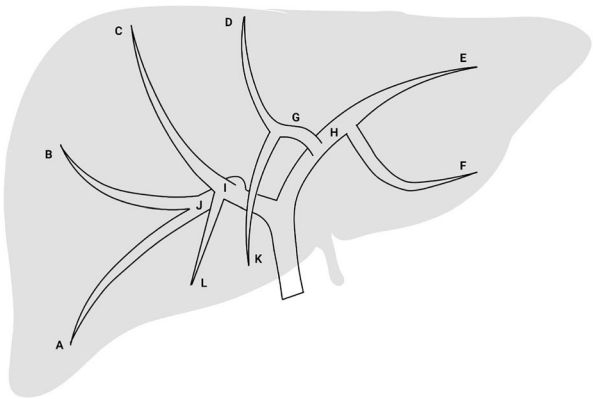

8. Left lateral sectoral: **H**
9. Left medial sectoral: **G**
10. Segment V: **L**
11. Segment VI: **A**
12. Segment VII: **B**
13. Segment IVa: **D**
14. Segment II: **E**
15. Right posterior sectoral: **J**
16. Segment VIII: **C**
17. Segment IVb: **K**
18. Right anterior sectoral: **I**
19. Segment III: **F**

20. Which of the following structures is NOT part of the extrahepatic biliary tree?[3]

    a. Left hepatic duct
    b. **Anterior sectoral right hepatic duct**
    c. Gallbladder
    d. Common hepatic duct

21. How much bile is produced in one day?[4]

    a. **650 ml per day**
    b. 850 ml per day
    c. 1250 ml per day
    d. 1550 ml per day

22. What is the arterial blood supply to the retropancreatic bile duct?[1]

    a. Dorsal pancreatic artery
    b. Right gastric artery
    c. Gastroduodenal artery
    d. **Retroduodenal artery**

23. The left hepatic duct is consistently present in most patients. However, in what proportion of patients is the left hepatic duct completely absent?[5,6]

    a. 0.05%
    b. **3%**
    c. 15%
    d. 41%

24. Which segments does the anterior sectoral right hepatic duct drain?[3]

    a. V and VI
    b. **V and VIII**
    c. VI and VII
    d. VII and VIII

25. Which hepatic duct is more frequently associated with anatomic variations? [5,7]

    a. **Right**
    b. Left
    c. Both have a similar incidence of anatomic variations

26. What is the embryologic origin of the extrahepatic bile duct?[8]

    a. Mesoderm
    b. Ectoderm
    c. **Endoderm**
    d. Hindgut

27. How frequently does the cystic duct drain to the right hepatic duct?[9]

    a. **Less than 1%**
    b. 14%
    c. 27%
    d. 48%

28. Which lymph node station is located along the common hepatic artery?[10]

    a. 12
    b. 11
    c. 9
    d. **8**



29. Choose the artery that does NOT provide blood supply to the extrahepatic bile duct.[1]

    a. Right hepatic
    b. Posterior superior pancreaticoduodenal
    c. Retroportal
    d. **Left gastric**

30. How many tributaries of the biliary tree drain segment I?[11]

    a. 1 or 2
    b. **3 or 4**
    c. 7 or 8
    d. 9 or 10

31. Choose the correct statement about the retroportal artery.[1]

    a. It originates from the proper hepatic artery
    b. It does not provide blood supply to the extrahepatic bile duct
    c. **It can originate from either the coeliac axis or the superior mesenteric artery**
    d. It is a fickle artery

Explanation in reference to the retroportal artery: it provides blood supply to the supraduodenal bile duct. It originates from either the superior mesenteric artery or the celiac trunk and passes posterior to the portal vein to reach the lower end of the supraduodenal duct.[1] It is present in 90% of patients.[2]

32. Which hepatic segments does the left hepatic duct typically drain?[3]

    a. **I, II, III, and IV**
    b. II, III, IV, and V
    c. V, VI, VII, and VIII
    d. II and III

33. Which corresponds to a normal biliary anatomy?[7,12]

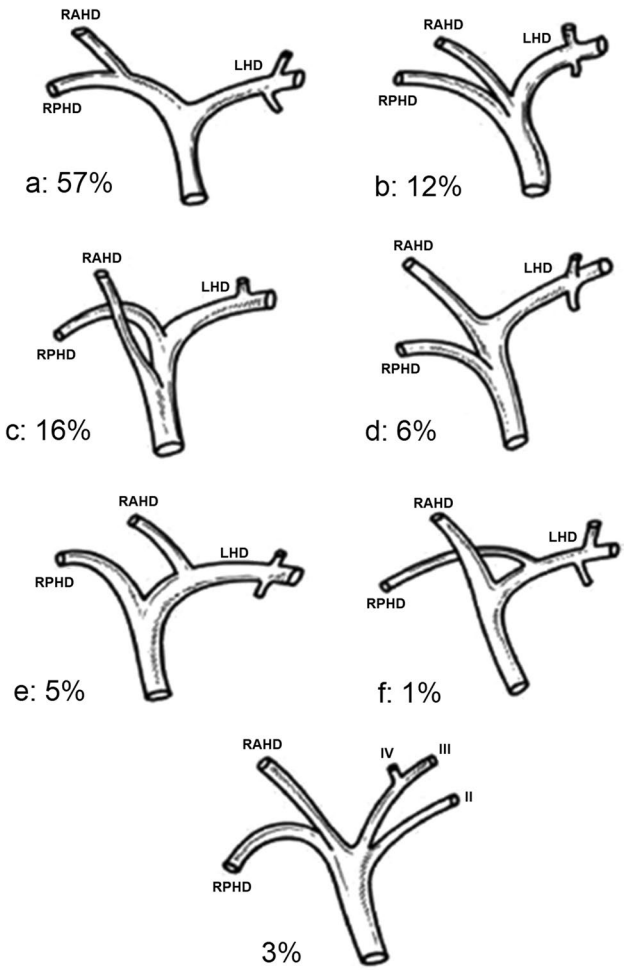

LHD: left hepatic duct, RAHD: right anterior hepatic duct, RPHD: right posterior hepatic duct

Answer: **a**

34. In the previously shown figure, which is the most frequent anatomical variation?[7,12]

Answer: **c**

35. Following a Whipple procedure, there is bile in the drain. Which of the following is a possible source of this leak?

a. Liver injury
b. Hepaticojejunostomy
c. Posterior sectoral right hepatic duct
d. **All of the above**

36. Select the most common confluence pattern of the right intrahepatic bile ducts described by Ohkubo et al.[13]:

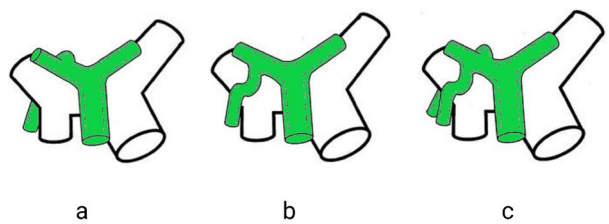

Answer: **a**

Explanation for questions 23, 24, and 31 to 34: the left hepatic duct has a long extrahepatic course and is present in 97% of the general population.[7,12] This consistency allows the performance of a side-to-side hepaticojejunostomy in cases of hepatic duct injury.[14]

Furthermore, as the right hepatic ducts have a higher rate of anatomical variations,[12,13] knowing them is vital. To illustrate, in an extended left hepatectomy (a major surgical challenge for any liver surgeon), the association between the portal vein anatomy and the course of the right posterior bile duct is an important piece of information for surgical planning.[15,16]

37. A 54-year-old patient presents with history of jaundice. Magnetic resonance cholangiopancreatography shows an obstruction of the biliary tree. Please choose the correct location of the obstruction.

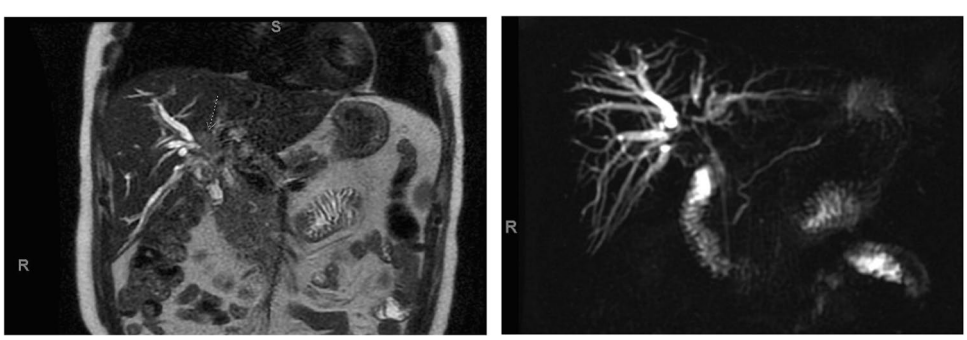

a. Left hepatic duct
b. Right posterior duct
c. **Right hepatic duct**
d. Common hepatic duct

38. A 64-year-old male presents a liver mass on CT (computed tomography) scan. It reveals occlusion of the right portal vein and right-sided bile duct dilation. What most accurately describes the following two images?[17]

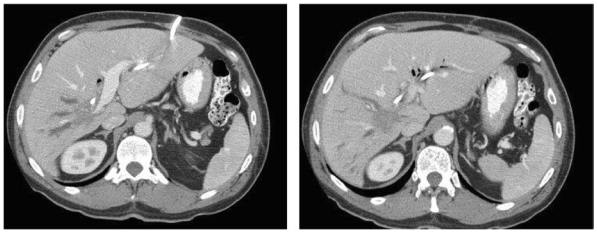

a. Cholestasis
b. Congestive right liver
c. Ischemia–reperfusion injury
d. **Atrophy-hypertrophy complex**

With the image presented in the previous question, underwent an extended right hepatectomy with hilar lymphadenectomy and portal vein reconstruction. Match the anatomic structures with the alphabetical labels shown in the figure:

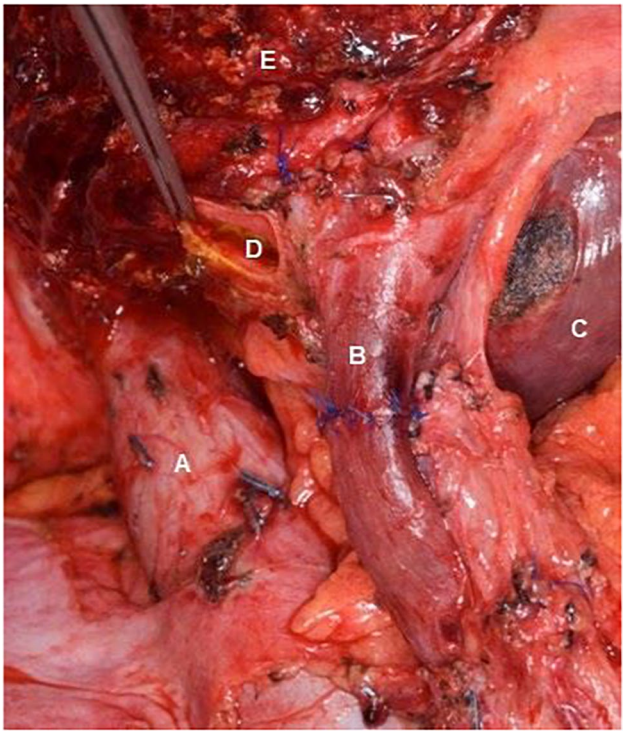

39. Liver capsule: **C**
40. Left hepatic duct: **D**
41. Inferior vena cava: **A**
42. Liver transection plane: **E**
43. Portal vein: **B**

44. In the following images, which segments do NOT show bile duct dilation?

a. II, III
b. VI, VII
c. **V, VIII**
d. IV, V

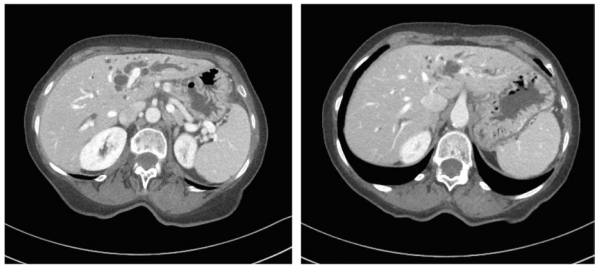

45. Who was the first to introduce intraoperative cholangiography in surgical practice?[18]

a. Claude Couinaud
b. Carl Hjortsjo
c. Erich Mühe
d. **Pablo Mirizzi**

Explanation: in 1932, Pablo Mirizzi reported the first series of routine intraoperative cholangiography during cholecystectomy. This imaging study allowed physicians to intraoperatively diagnose and concurrently treat a bile duct injury or choledocholithiasis.

46. What is Mirizzi's syndrome?[19]

a. It is a malignant obstruction of the common hepatic duct obstruction due to gallbladder cancer
b. **It is a benign obstruction of the common hepatic duct due to gallstone impaction in the gallbladder neck**
c. It is a malignant obstruction of the common hepatic duct due to hilar cholangiocarcinoma
d. It is a benign obstruction of the common hepatic duct due to stones in the biliary tract

47. Which of the following is NOT a predisposing factor for the development of Mirizzi's syndrome?[20]

    a. Long cystic duct
    b. Cystic duct with a parallel course to the common bile duct
    c. Low insertion of the cystic duct
    d. **Gallstone > 1 cm**

48. Select the correct statement[21]:

    a. **Bile from the caudate lobe drains into both the right and left hepatic ducts near the confluence**
    b. Hilar cholangiocarcinoma rarely invades segment I
    c. The caudate lobe forms part of the anterior limit of the hilar plate
    d. The caudate process is the most readily identified portion of segment I

49. What common bile duct width is highly indicative of biliary obstruction?[22]

    a. **> 8 mm**
    b. > 10 mm
    c. > 12 mm
    d. > 14 mm

50. Which factor is associated with an increase in the common bile duct diameter without obstruction?[23,24]

    a. > 70 years old
    b. Previous cholecystectomy
    c. Opiate users
    d. **All of the above**

51. What is the most frequent bacterial colonizer of the bile duct?[25]

    a. *Escherichia coli*
    b. *Staphylococcus aureus*
    c. *Klebsiella pneumoniae*
    d. **None, bile is sterile in normal conditions**

52. Intraoperatively, which is an essential study to assess biliary anatomy?[26]

    a. Magnetic resonance cholangiopancreatography (MRCP)
    b. **Cholangiography**
    c. Endoscopic retrograde cholangiopancreatography (ERCP)
    d. Ultrasound

Explanation to questions 49, 50, and 51: there is some debate on the average normal common bile duct diameter. Studies suggest that it is approximately 3–7 mm with a gallbladder in situ.[22,27] However, this value increases with older age (>70 years old),[24] history of cholecystectomy,[24] and opiate usage.[23]

The armamentarium used to assess the presence, level, and cause of obstruction is diverse, but each imaging study has its pros and cons that make it suitable for a specific context.[28]

53. Who was the first to describe the sheaths surrounding the portal pedicles?[29]

    a. Francis Glisson
    b. **Johannes Walaeus**
    c. J. E. Healey Jr
    d. Hugo Rex

Explanation: Francis Glisson described a sheath surrounding the portal triad in 1659.[30] However, in 1640, the Dutch physician Johannes Walaeus had originally described this finding.[29]

54. What is the structure depicted by the yellow arrow?

    a. Right hepatic duct
    b. **Segment VII bile duct**
    c. Segment V bile duct
    d. Right anterior sectoral duct

Explanation: this patient has bilateral biliary tract dilation, allowing for visualization of the intrahepatic biliary tree on a CT scan

55. What is the double duct sign in radiographic imaging and what does it mean?[31]

a. **It shows simultaneous dilation of the common bile duct and the pancreatic duct. It is most commonly due to a mass in the pancreatic head**
b. It shows both the common bile duct and cystic duct adjacent to each other. This signifies an anatomic variation of the cystic duct
c. It shows the dilation of both the main and accessory pancreatic duct, and signifies a mass in the pancreatic head
d. It shows and signifies dissected common bile duct wall

56. Which of the following statements about the structure indicated by the yellow arrow is true?

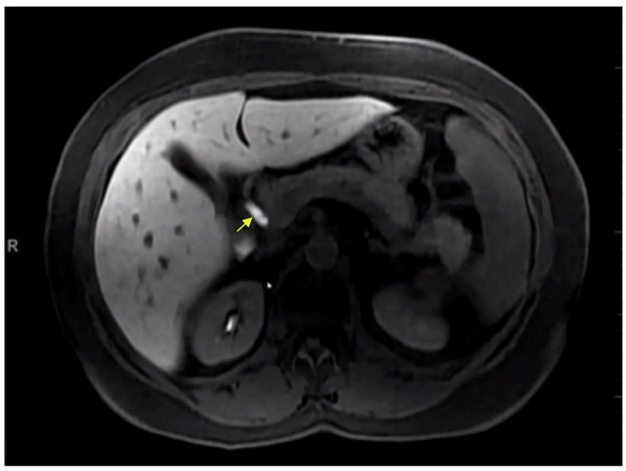

a. This is the common hepatic artery and is seen after 25 s of contrast infusion with gadolinium
b. **This is the common bile duct and is seen after 20 min of contrast infusion on MR Eovist**
c. This is the proper hepatic artery and is seen after 15 s of contrast infusion with gadolinium
d. None of the above

57. Which is the most frequently observed anatomical variation of the pancreaticobiliary junction?[3,32]

a. Both ducts enter the duodenum separately, no ampulla is present (85%)
b. Both ducts enter together, but the common channel is short, and no true ampulla is present (85%)
c. **There is a long common channel that may or may not be dilated to form an ampulla (85%)**
d. Junction of the ducts take place at the third portion of the duodenum, and the common channel always presents an ampulla (85%)

58. Which of the following statements about choledochal cysts is true?[33]

a. Most of them are diagnosed within the first decade of life
b. They are most common in females and Asian population
c. Pancreaticobiliary maljunction is the most common etiology of this entity
d. **All of the above**

59. Which type of choledochal cyst is depicted in the illustration? What is its relative frequency?[34,35]



a. Type II, it is the least common
b. Type IVb, it is the least common
c. **Type I, it is the most common**
d. Type V, it is the most common

60. What should be the correct treatment strategy for this type of choledochal cyst?[35]

a. ERCP with stent placement
b. **Extrahepatic bile duct cyst excision, cholecystectomy, and bilioenteric reconstruction**
c. Cystenterostomy
d. All of the above

61. Which of the following statements best describes Caroli's disease?[36,37]

a. It presents with multiple intrahepatic bile duct cysts
b. It consists of rounded or oval intrahepatic bile duct dilatations separated by segments of normal caliber
c. Treatment consists of biliary drainage, resection, or liver transplant depending on its extension
d. **All of the above**

62. The gallbladder is divided into[38]:

a. Fundus, infundibulum, neck
b. **Fundus, body, neck**
c. Fundus, body, infundibulum, Hartman's pouch, neck
d. Fundus, body, infundibulum, neck, cystic duct

63. Which hepatic segments form the gallbladder bed?

a. IVa and V
b. IVb and VI
c. **IVb and V**
d. IVa and V

64. Choose the layer that is absent in the gallbladder wall[39]:

a. Mucosa
b. **Submucosa**
c. Muscular
d. Serosa

Explanation: knowledge about gallbladder wall composition is crucial for the management of gallbladder cancer. In this malignancy, the depth of tumor penetration is the most important prognostic factor.

T1 is further subdivided into T1a (tumor that invades the lamina propria) and T1b (tumor that invades the muscle layer). Cholecystectomy alone is the accepted treatment strategy for T1a tumors.[40] On the other hand, T1b tumors are the motive of discussion. Some argue radical cholecystectomy is the treatment of choice; however, others oppose this.[41,42]

Moreover, T2 (tumor that reached the subserosal layer) has been associated with worse 5-year overall survival compared to T1 (56.1% vs 85.9%).[43] Shindoh et al. further subdivided this into T2a (tumor on the peritoneal side) and T2b (tumor on the hepatic side). The latter was associated with worse overall survival.

65. What is the triangle of Calot?[44]

a. It is an anatomic space bordered by the cystic duct inferiorly, the common hepatic duct medially, and the inferior surface of the liver superiorly
b. It is the liver surface that is in touch with the duodenum
c. It is the deperitonized liver surface
d. It is an anatomic space bordered by the right hepatic artery inferiorly, the common hepatic duct medially, and the inferior surface of the liver superiorly

66. The triangle of Calot contains which of the following structures[44]:

a. Cystic artery
b. Cystic lymph node of Lund
c. Right hepatic artery
d. **All of the above**

67. Which is a requirement to achieve a critical view of safety during laparoscopic cholecystectomy?[45]

a. The triangle of Calot cleared of fat and tissue
b. The lowest part of the gallbladder should be separated from the cystic plate
c. Two structures, and only two, should be seen entering the gallbladder
d. **All of the above**

68. A normal non-inflamed gallbladder has[46]:

a. A wall thickness of 8 mm or less
b. Pericholecystic fluid
c. **Its anteroposterior diameter of less than 40 mm**
d. Sludge

69. Which of the following statements about the cystic duct is true?[9]

    a. It most commonly inserts on the left lateral aspect of the common bile duct
    b. **Low insertion is defined as joining at the lower third of the common hepatic duct**
    c. A short cystic duct is defined as < 10 mm long
    d. None of the above

70. What is the definition of a left-sided gallbladder?[47]

    a. **The gallbladder located to the left of the ligamentum teres**
    b. The gallbladder located to the left of the common bile duct
    c. The gallbladder located to the left of the portal vein
    d. The gallbladder located at the left upper quadrant

71. Who was the first to ever perform a laparoscopic cholecystectomy?[48]

    a. Claude Couinaud
    b. Carl Hjortsjo
    c. **Erich Mühe**
    d. Pablo Mirizzi

72. What is a duct of Luschka?[49]

    a. It is a segment I bile duct that drains directly in the common hepatic duct
    b. It is a segment V aberrant duct draining directly into the common hepatic duct
    c. It is a hepaticocholecystic bile duct that always runs into the gallbladder
    d. **It is a subvesical bile duct that either runs superficially close to or inserts in the gallbladder**

73. The gallbladder is in contact with which of the following organs?

    a. Liver
    b. Duodenum
    c. Transverse colon
    d. **All of the above**

74. Which of the following statements about the duplicated gallbladders is true?[50].

    a. It occurs much more frequently in humans than in animals
    b. They always share a common cystic duct
    c. **Differential diagnosis includes folded gallbladder, a gallbladder diverticulum, a choledochal cyst, pericholecystic fluid, and focal adenomyomatosis**
    d. A and C are correct

75. Which of the following statements about gallbladder polyps is true?[51–53]

    a. Transabdominal ultrasound is the first-line imaging study for diagnosis, but in certain cases cross-sectional imaging is necessary
    b. Factors that suggest malignancy are: > 50 years old, larger than 1.5 cm, growth, sessile, solitary, and heterogeneous enhance pattern
    c. Small (< 1 cm), asymptomatic polyps should be monitored for 12 months with control ultrasound scans
    d. **All of the above**

76. Which of the following about the cystic artery and its frequency of variants is true?[3,32]

    a. 74.7% of the time the cystic artery arises from the right hepatic artery
    b. 2.5% of the time the cystic artery arises from the gastroduodenal artery
    c. 20.5% of the time the cystic artery arises from the left hepatic artery
    d. **All of the above**

77. What is a "Phrygian cap" deformity of the gallbladder?[3,54]

    a. The presence of a small accessory gallbladder attached to the main one
    b. **A partial folding of the fundus of the gallbladder**
    c. An almost completely intrahepatic gallbladder with only the fundus exposed
    d. A benign circumferential tumor of the gallbladder

78. What is the diagnosis associated with the imaging presented below?[55]

a. This is a "beads on a string" appearance of the bile ducts. It signifies primary biliary cholangitis
b. **This is a "beads on a string" appearance of the bile ducts. It signifies primary sclerosing cholangitis.**
c. This is onion skinning appearance, and it signifies primary sclerosing cholangitis.
d. This is onion skinning appearance, and it signifies primary biliary cholangitis

79. What are the possible causes of the sign depicted in the image?

a. **Air in the biliary tree caused by bile duct stenting**
b. Blood in the biliary tree caused by bile duct stenting
c. Air in the biliary tree caused by a pancreatic head mass
d. Blood in the biliary tree caused by tumoral invasion

Acknowledgements The authors thank Ms. Ruth Haynes for administrative support in the preparation of this manuscript.

Author Contribution Study concept and design: Mateo Lendoire, Harufumi Maki, Antony Haddad, Jean-Nicolas Vauthey.

Article review: all authors

Article preparation: Mateo Lendoire, Harufumi Maki, Antony Haddad, Jean-Nicolas Vauthey.

Article editing: all authors.

Final approval: all authors.

Funding Supported by the National Institutes of Health through MD Anderson Cancer Center Support Grant CA016672.

Declarations

Conflict of Interest The authors declare no competing interests.

References

1. Northover JM, Terblanche J. A new look at the arterial supply of the bile duct in man and its surgical implications. Br J Surg. 1979;66(6):379-84. doi:https://doi.org/10.1002/bjs.1800660603.
2. Chen WJ, Ying DJ, Liu ZJ, He ZP. Analysis of the arterial supply of the extrahepatic bile ducts and its clinical significance. Clin Anat. 1999;12(4):245-9. doi:https://doi.org/10.1002/(sici)1098-2353(1999)12:4<245::Aid-ca2>3.0.Co;2-w
3. Skandalakis LJ. Surgical anatomy of the liver and associated extrahepatic structures. Bobit Publ; 1987.
4. Esteller A. Physiology of bile secretion. World J Gastroenterol. 2008;14(37):5641-9. doi:https://doi.org/10.3748/wjg.14.5641.
5. Couinaud C. Le Foie: Etudes Anatomiques et chirurgicales. Paris: Masson & Cia; 1957.
6. Launois B, Cubertafond P. Les cancers des voies biliaires extrahépatiques: Rapport présenté AU. Paris: Masson; 1988.
7. Vauthey JN, Zimmitti G, Shindoh J. From Couinaud to molecular biology: the seven virtues of hepato-pancreato-biliary surgery. HPB (Oxford). 2012;14(8):493-9. doi:https://doi.org/10.1111/j.1477-2574.2012.00502.x.
8. Adkins RB, Jr., Chapman WC, Reddy VS. Embryology, anatomy, and surgical applications of the extrahepatic biliary system. Surg Clin North Am. 2000;80(1):363-79. doi:https://doi.org/10.1016/s0039-6109(05)70410-2.
9. Sarawagi R, Sundar S, Gupta SK, Raghuwanshi S. Anatomical Variations of Cystic Ducts in Magnetic Resonance Cholangiopancreatography and Clinical Implications. Radiol Res Pract. 2016;2016:3021484. doi:https://doi.org/10.1155/2016/3021484.
10. Nakamura T, Hojo Y, Kumamoto T, Kurahashi Y, Ishida Y, Shinohara H. History of the lymph node numbering system in the Japanese Classification of Gastric Carcinoma since 1962. Surg Today. 2022;52(11):1515-23. doi:https://doi.org/10.1007/s00595-021-02395-2.
11. Kumon M. Anatomical Study of the Caudate Lobe with Special Reference to Portal Venous and Biliary Branches Using Corrosion Liver Casts and Clinical Application. Liver Cancer. 2017;6(2):161-70. doi:https://doi.org/10.1159/000454682.
12. Couinaud C, Delmas A, Patel J. Le Foie: Études Anatomiques et chirurgicales. Paris: Masson; 1957.
13. Ohkubo M, Nagino M, Kamiya J, Yuasa N, Oda K, Arai T et al. Surgical anatomy of the bile ducts at the hepatic hilum as applied to living donor liver transplantation. Ann Surg. 2004;239(1):82-6. doi:https://doi.org/10.1097/01.sla.0000102934.93029.89.
14. Hepp J, Couinaud C. L'abord et l'utilisation du canal hépatique gauche dans les réparations de la voie biliaire principale. Presse Med. 1956;64(41):947-8.
15. Watanabe N, Ebata T, Yokoyama Y, Igami T, Sugawara G, Mizuno T et al. Anatomic features of independent right posterior portal vein variants: Implications for left hepatic trisectionectomy. Surgery. 2017;161(2):347-54. doi:https://doi.org/10.1016/j.surg.2016.08.024.
16. Vauthey JN, Yamashita S. Perfecting a challenging procedure: The Nagoya portal vein guide to left trisectionectomy. Surgery. 2017;161(2):355-6. doi:https://doi.org/10.1016/j.surg.2016.07.030.
17. Kim RD, Kim JS, Watanabe G, Mohuczy D, Behrns KE. Liver regeneration and the atrophy-hypertrophy complex. Semin Intervent Radiol. 2008;25(2):92-103. doi:https://doi.org/10.1055/s-2008-1076679.
18. Mirizzi P. La colangiografia durante las operaciones de las vias biliares. Bol Soc Cir Buenos Aires. 1932;16:1133.
19. Csendes A, Diaz JC, Burdiles P, Maluenda F, Nava O. Mirizzi syndrome and cholecystobiliary fistula: A unifying classification. British Journal of Surgery. 2005;76(11):1139-43. doi:https://doi.org/10.1002/bjs.1800761110.
20. Beltrán MA. Mirizzi syndrome: history, current knowledge and proposal of a simplified classification. World J Gastroenterol. 2012;18(34):4639-50. doi:https://doi.org/10.3748/wjg.v18.i34.4639.
21. Abdalla EK, Vauthey JN, Couinaud C. The caudate lobe of the liver: implications of embryology and anatomy for surgery. Surg Oncol Clin N Am. 2002;11(4):835-48. doi:https://doi.org/10.1016/s1055-3207(02)00035-2.
22. Niederau C, Müller J, Sonnenberg A, Scholten T, Erckenbrecht J, Fritsch WP et al. Extrahepatic bile ducts in healthy subjects, in patients with cholelithiasis, and in postcholecystectomy patients: a prospective ultrasonic study. J Clin Ultrasound. 1983;11(1):23-7. doi:https://doi.org/10.1002/jcu.1870110106.
23. Barakat MT, Banerjee S. Incidental biliary dilation in the era of the opiate epidemic: High prevalence of biliary dilation in opiate users evaluated in the Emergency Department. World J Hepatol. 2020;12(12):1289-98. doi:https://doi.org/10.4254/wjh.v12.i12.1289.
24. Benjaminov F, Leichtman G, Naftali T, Half EE, Konikoff FM. Effects of age and cholecystectomy on common bile duct diameter as measured by endoscopic ultrasonography. Surg Endosc. 2013;27(1):303-7. doi:https://doi.org/10.1007/s00464-012-2445-7.
25. Csendes A, Fernandez M, Uribe P. Bacteriology of the gallbladder bile in normal subjects. Am J Surg. 1975;129(6):629-31. doi:https://doi.org/10.1016/0002-9610(75)90334-7.
26. Imamura H, Makuuchi M, Sakamoto Y, Sugawara Y, Sano K, Nakayama A et al. Anatomical keys and pitfalls in living donor liver transplantation. J Hepatobiliary Pancreat Surg. 2000;7(4):380-94. doi:https://doi.org/10.1007/s005340070033.
27. Parulekar SG. Ultrasound evaluation of common bile duct size. Radiology. 1979;133(3 Pt 1):703-7. doi:https://doi.org/10.1148/133.3.703.
28. Tse F, Barkun JS, Romagnuolo J, Friedman G, Bornstein JD, Barkun AN. Nonoperative imaging techniques in suspected biliary tract obstruction. HPB (Oxford). 2006;8(6):409-25. doi:https://doi.org/10.1080/13651820600746867.
29. Walaeus J, Bataviae TBAL. Epistolae duae de motu chili et sanguinis ad Thomam Bartholeum. Thomas Bartholeus Anatomica Lugd. Bataviae (Leyden) Franciscus Hackius. 1640.
30. Glisson F. Francisci glissonii anatomia hepatis: Cui Praemittuntur quaedam ad Rem Anatomicam Universe Spectantia. Ravestein; 1659.
31. Soto JA, Alvarez O, Lopera JE, Múnera F, Restrepo JC, Correa G. Biliary obstruction: findings at MR cholangiography and cross-sectional MR imaging. Radiographics. 2000;20(2):353-66. doi:https://doi.org/10.1148/radiographics.20.2.g00mc06353.
32. Michels NA. Blood supply and anatomy of the upper abdominal organs: With a descriptive Atlas. London: Pitman Medical; 1955.

33. Yamaguchi M. Congenital choledochal cyst. Analysis of 1,433 patients in the Japanese literature. Am J Surg. 1980;140(5):653–7. https://doi.org/10.1016/0002-9610(80)90051-3.
34. Todani T, Watanabe Y, Narusue M, Tabuchi K, Okajima K. Congenital bile duct cysts: Classification, operative procedures, and review of thirty-seven cases including cancer arising from choledochal cyst. Am J Surg. 1977;134(2):263-9. doi:https://doi.org/10.1016/0002-9610(77)90359-2.
35. Nicholl M, Pitt HA, Wolf P, Cooney J, Kalayoglu M, Shilyansky J et al. Choledochal cysts in western adults: complexities compared to children. J Gastrointest Surg. 2004;8(3):245-52. doi:https://doi.org/10.1016/j.gassur.2003.12.013.
36. Abdalla EK, Forsmark CE, Lauwers GY, Vauthey JN. Monolobar Caroli's Disease and cholangiocarcinoma. HPB Surg. 1999;11(4):271–6; discussion 6–7. https://doi.org/10.1155/1999/70985.
37. Caroli J, Couinaud C. Une affection nouvelle, sans doute cong6nitale, des voies biliaires. La dilatation kystique unilobaire des canaux h6patiques. Semaines des Hopitaux Paris. 1958;34:136–42.
38. Nagral S. Anatomy relevant to cholecystectomy. J Minim Access Surg. 2005;1(2):53-8. doi:https://doi.org/10.4103/0972-9941.16527.
39. Of journal "Morphologia Eo. Histology: A Text and Atlas: With Correlated Cell and Molecular Biology. Eighth Edition, 2018 Authors: Wojciech Pawlina; Michael H. Ross. Morfolihĩĩa. 2019;13(4):76–89. https://doi.org/10.26641/1997-9665.2019.4.76-89.
40. Goetze TO, Paolucci V. Immediate re-resection of T1 incidental gallbladder carcinomas: a survival analysis of the German Registry. Surg Endosc. 2008;22(11):2462-5. doi:https://doi.org/10.1007/s00464-008-9747-9.
41. Toyonaga T, Chijiiwa K, Nakano K, Noshiro H, Yamaguchi K, Sada M et al. Completion radical surgery after cholecystectomy for accidentally undiagnosed gallbladder carcinoma. World J Surg. 2003;27(3):266-71. doi:https://doi.org/10.1007/s00268-002-6609-9.
42. Liang YC, Li SG, Wang JY. Radical Resection Versus Simple Cholecystectomy for Gallbladder Carcinoma: A Systematic Review and Meta-analysis. Surg Laparosc Endosc Percutan Tech. 2020;30(4):381-7. doi:https://doi.org/10.1097/sle.0000000000000789.
43. Miyakawa S, Ishihara S, Horiguchi A, Takada T, Miyazaki M, Nagakawa T. Biliary tract cancer treatment: 5,584 results from the Biliary Tract Cancer Statistics Registry from 1998 to 2004 in Japan. J Hepatobiliary Pancreat Surg. 2009;16(1):1-7. doi:https://doi.org/10.1007/s00534-008-0015-0.
44. Abdalla S, Pierre S, Ellis H. Calot's triangle. Clin Anat. 2013;26(4):493-501. doi:https://doi.org/10.1002/ca.22170.
45. Strasberg SM, Brunt LM. Rationale and use of the critical view of safety in laparoscopic cholecystectomy. J Am Coll Surg. 2010;211(1):132-8. doi:https://doi.org/10.1016/j.jamcollsurg.2010.02.053.
46. Gallaher JR, Charles A. Acute Cholecystitis: A Review. Jama. 2022;327(10):965-75. doi:https://doi.org/10.1001/jama.2022.2350.
47. Nagai M, Kubota K, Kawasaki S, Takayama T, BandaiY, Makuuchi M. Are left-sided gallbladders really located on the left side? Ann Surg. 1997;225(3):274–80. https://doi.org/10.1097/00000658-199703000-00006.
48. Reynolds W, Jr. The first laparoscopic cholecystectomy. Jsls. 2001;5(1):89-94.
49. Schnelldorfer T, Sarr MG, Adams DB. What is the duct of Luschka?--A systematic review. J Gastrointest Surg. 2012;16(3):656-62. doi:https://doi.org/10.1007/s11605-011-1802-5.
50. Janson JA, Gulliver D, Cotton PB. Choledocholithiasis and a double gallbladder. Gastrointest Endosc. 1992;38(3):377-9. doi:https://doi.org/10.1016/s0016-5107(92)70438-6.
51. Andrén-Sandberg A. Diagnosis and management of gallbladder polyps. N Am J Med Sci. 2012;4(5):203-11. doi:https://doi.org/10.4103/1947-2714.95897.
52. Riddell ZC, Corallo C, Albazaz R, Foley KG. Gallbladder polyps and adenomyomatosis. Br J Radiol. 2022:20220115. https://doi.org/10.1259/bjr.20220115.
53. Okaniwa S. How Can We Manage Gallbladder Lesions by Transabdominal Ultrasound? Diagnostics (Basel). 2021;11(5). https://doi.org/10.3390/diagnostics11050784.
54. Kokilavani J, Indiran V. Phrygian cap. Abdom Radiol (NY). 2018;43(5):1264-5. doi:https://doi.org/10.1007/s00261-017-1262-9.
55. Morgan MA. Primary sclerosing cholangitis. Radiopaedia.org. 2021. https://radiopaedia.org/cases/88262.

Publisher's Note Springer Nature remains neutral with regard to jurisdictional claims in published maps and institutional affiliations.

Springer Nature or its licensor (e.g. a society or other partner) holds exclusive rights to this article under a publishing agreement with the author(s) or other rightsholder(s); author self-archiving of the accepted manuscript version of this article is solely governed by the terms of such publishing agreement and applicable law.